

# Comparison of Digital Subtraction Angiography and Non-Contrast-Enhanced Magnetic Resonance Angiography Findings in Imaging Carotid Arteries

Kemal Bugra Memis<sup>1</sup>, Ali Osman Gulmez<sup>1</sup>, Umman Sanlıdilek<sup>2</sup>

<sup>1</sup>Department of Radiology, Erzincan Binali Yıldırım University Faculty of Medicine, Erzincan, Türkiye

<sup>2</sup>Department of Radiology, Ankara University Faculty of Medicine, Ankara, Türkiye

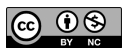**Cite this article as:** Memis KB, Gulmez AO, Sanlıdilek U. Comparison of digital subtraction angiography and non-contrast-enhanced magnetic resonance angiography findings in imaging carotid arteries. *Current Research in MRI*, 2024;3(2):49-56.

**Corresponding author:** Kemal Bugra Memis, e-mail: kemalbugramemis@gmail.com

**Received:** May 28, 2024 **Revision requested:** August 5, 2024 **Last revision received:** August 15, 2024 **Accepted:** August 16, 2024

**Publication Date:** August 27, 2024

DOI:10.5152/CurrResMRI.2024.24097



Content of this journal is licensed under a Creative Commons Attribution-NonCommercial 4.0 International License.

## Abstract

**Objective:** This study aimed to compare the diagnostic effectiveness and precision of non-contrast magnetic resonance angiography (MRA) with the most reliable digital subtraction angiography (DSA) findings in imaging the cervical segment of the carotid arteries.

**Methods:** From January 2012 to April 2018, a retrospective evaluation was conducted on the images of 23 patients who had undergone DSA and non-contrast MRA for the carotid arteries in the neck. The evaluation was based on data retrieved from the local database. The stenosis rates were categorized as follows: normal, stenosis less than 50%, stenosis between 50% and 69%, stenosis equal to or greater than 70%, and total occlusion.

**Results:** Out of the 23 participants who were included in the study, 13 (56.5%) were female and 10 (43.5%) were male. The average age of the patients was 58.5, with a range of 29 to 84 and a median value of 60. The non-contrast MRA examination had a sensitivity of 78%, specificity of 97%, positive predictive value of 88%, negative predictive value of 95%, and diagnostic accuracy of 93% for detecting significant stenosis (>50%) in the internal carotid artery (ICA), as determined by the gold standard DSA. The non-contrast MRA had a sensitivity of 86%, specificity of 100%, positive predictive value of 100%, negative predictive value of 98%, and a diagnostic accuracy rate of 98%.

**Conclusion:** Non-contrast MRA imaging is a secure technique for identifying atherosclerotic carotid artery disease with a high level of accuracy and precision.

**Keywords:** Digital subtraction angiography, extracranial carotid arteries, non-contrast MR angiography

## INTRODUCTION

Cerebrovascular disease, such as strokes, is a leading cause of mortality in developed nations. The occurrence results from either hemodynamic or, more commonly, atheroembolic mechanisms, which are caused by atherosclerotic plaques of the carotid bifurcation in approximately 15%-20% of cases.<sup>1</sup> Given that plaques in the extracranial carotid arteries are responsible for 25% of ischemic cerebrovascular events that result in chronic neurological deficiencies, it is crucial to prioritize the treatment of these abnormalities.<sup>2</sup> Options for treatment consist of endarterectomy or percutaneous transluminal carotid angioplasty and stenting, which is a radiological procedure performed by interventional means. Medical interventions for mitigating risk factors are also encompassed. Accurate and precise measurement of the extent of stenosis is crucial in selecting the suitable treatment.<sup>3</sup>

Digital subtraction angiography (DSA) is considered the most reliable method for imaging the carotid arteries. However, noninvasive imaging techniques like magnetic resonance angiography (MRA), computed tomographic angiography (CTA), and color Doppler ultrasonography (CDUS) also have a significant role in evaluating the carotid arteries.<sup>4</sup>

Color Doppler ultrasonography, a readily available and minimally invasive procedure, is frequently employed as the initial diagnostic imaging technique for screening carotid artery stenosis. However, the outcome is greatly influenced by the user's level of expertise and proficiency. Digital subtraction angiography, which is considered the standard for determining the severity of narrowing in blood vessels and the characteristics of plaque, is not universally applicable to all patients due to the associated hazards and expenses. Currently, non-invasive techniques such as CTA and MRA are becoming more commonly utilized for diagnosing carotid stenosis, replacing the need for invasive DSA.<sup>3</sup> Computed tomographic angiography is the primary diagnostic technique for imaging blood vessels in cases of sudden stroke.<sup>5</sup> Nevertheless, it is important to note that the procedure involves ionizing radiation, and the intravenous contrast material utilized can cause allergic reactions and have nephrotoxicity effects.

Furthermore, MRA is both noninvasive and spared from ionizing radiation. Currently, the most common method for imaging the carotid arteries is through the use of contrast-enhanced MRA. This involves injecting gadolinium-based contrast agents via an intravenous route. Magnetic resonance imaging contrast agents have minimal adverse effects; however, they can induce nephrogenic systemic fibrosis in individuals with renal insufficiency. The awareness of this potential side effect and the existence of patients who are unable to undergo contrast administration for various reasons have resulted in a growing interest in non-contrast MRA in recent times. The prevailing non-contrast MRA technique that is frequently utilized is known as “time-of-flight” (TOF) angiography.<sup>4</sup> The primary constraints of MRA are motion artifacts caused by patient noncompliance and intolerance in individuals experiencing acute stroke. Furthermore, it is contraindicated in patients with pacemakers and certain magnetic devices.<sup>5,6</sup>

The purpose of this study was to compare the results of non-contrast MRA and DSA, which is considered the most reliable method in our center, for imaging the cervical segments of carotid arteries. Additionally, we aimed to assess the diagnostic efficiency and accuracy of the non-contrast MRA technique.

## MATERIAL AND METHODS

The study was initiated with the approval of the Ankara University Faculty of Medicine Clinical Research Ethics Committee (Date: 2014, Decision No: 06-355-18). All patients provided written informed consent for the publication of this article using their data.

A retrospective analysis was conducted on 29 patients who underwent both DSA and non-contrast MRA scans for carotid arteries at our hospital between January 2012 and April 2018. Initially, 4 patients were excluded from the study because more than 1 year had passed between the 2 examinations. In addition, we excluded 2 patients from the study because their images were affected by motion artifacts in MRA and artifacts caused by stents in the carotid arteries. For the remaining 23 cases, the carotid arteries in the neck were divided into the right and left common carotid artery (CCA), internal carotid artery (ICA), and external carotid artery (ECA). These arteries were then assessed individually using both methods from the PACS database. An experienced radiologist evaluated the existing images without knowledge of the patients' clinical data. The DSA images were evaluated separately from the initial evaluation, which took place 4 weeks after the MRA images were evaluated initially. Subsequently, this assessment procedure was reiterated once again at 4-week intervals. Stenosis rates were determined using the North American Symptomatic Carotid Endarterectomy Trial (NASCET) criteria and categorized as “normal,” “<50% stenosis,” “50%-69% stenosis,” “≥70% stenosis,” and total occlusion.

## MAIN POINTS

- Non-invasive non-contrast MRA can be used as an alternative to DSA, an invasive method, for diagnosing atherosclerotic carotid artery disease, even though DSA is considered the gold standard.
- Non-contrast MRA can be utilized as an adjunct imaging technique in patients with impaired renal function, particularly when CDUS is insufficient in visualizing the carotid arteries. This method does not necessitate the use of nephrotoxic agents.
- Non-contrast MRA is more useful in populations that are averse to ionizing radiation.

All non-contrast MRA examinations were obtained with the time of flight (TOF) angiography technique. Fifteen of these scans were conducted using a 3.0 T magnetic resonance imaging (MRI) scanner (Siemens Magnetom Verio, Erlangen, Germany), while 8 were performed using a 1.5 T MRI scanner (Siemens Magnetom Aera, Erlangen, Germany). The acquisition parameters in the axial 3D TOF MRA examination performed with a 3.0 T device were determined as TR 21 ms, TE 3.6 ms, deviation angle 25 degrees, slice thickness 1 mm, matrix 384 × 312, FOV 20 × 16 cm. The acquisition parameters in the axial 3D TOF MRA examination performed with a 1.5 T device were determined as TR 24 ms, TE 7.2 ms, deviation angle 20 degrees, section thickness 0.8-1 mm, matrix 512 × 512, FOV 20 × 16 cm.

The DSA techniques were executed using an Artis Zee (Siemens Healthcare, Erlangen, Germany) angiography device. The patients underwent the procedure without the administration of sedation. Following the application of povidone-iodine solution for local field sterilization, the femoral artery was utilized as the access route after the application of dressing and local anesthesia. Following the puncture using the Seldinger method, a 5-French sheath was inserted into the femoral artery. The pigtail angiography catheter was inserted through the sheath and used to visualize the aortic arch and its branches. The carotid artery exits were identified based on the images, and subsequently, a Simmons type II catheter was used to selectively catheterize the carotid arteries after replacing the catheter. Next, conventional images of the carotid arteries were acquired in anteroposterior, lateral, and oblique orientations for both the right and left sides. During the examination, the patient received a suitable dose of nonionic contrast material based on their weight, with a maximum limit of 100 mL, using an automatic pump injector.

The stenoses were assessed on both DSA and MRA images using the NASCET criteria (stenosis =  $[1 - \text{minimal residual lumen/distal vascular lumen diameter}] \times 100\%$ ). During the DSA method, the degree of stenosis in the carotid arteries was assessed by measuring the percentage of narrowing. This measurement was taken from all projections that provided a clear view of the carotid arteries without any overlapping blood vessels. The most severe narrowing of the artery was chosen, and its representation was recorded. The main datasets of 3D TOF and maximum intensity projection (MIP) images were examined. The degree of stenosis in the carotid arteries was assessed using sagittal and coronal MIP images, and the most severe degree of stenosis was recorded. When the presence of occlusion was suspected in 3D TOF MIP images, the potential occurrence of slow flow was ruled out by assessing 2D TOF images. If there was no detected blood flow in the expected pathway beyond the examined artery, the vessel was classified as totally obstructed. The assessment of the image was conducted using the Syngo MR software (Siemens Medical Solutions, Erlangen, Germany) on a workstation.

The gold standard for detecting carotid artery stenosis was accepted as DSA. Sensitivity, specificity, positive predictive value (PPV), and negative predictive value (NPV) were calculated for the non-contrast MRA examination. Furthermore, observer agreement was assessed using the kappa correlation test. The provided information includes the mean ± SD for numerical variables, the minimum and maximum values (min-max), and the number and percentage values for categorical variables. The relationship between the features was analyzed at the qualitative measurement level using either Fisher's exact test or Pearson's chi-square test. The statistical analysis was conducted using the SPSS 25.0 software (IBM SPSS Corp.;

Armonk, NY, USA). Statistical significance was determined by a *P*-value threshold of less than .05.

## RESULTS

Out of the total of 23 participants who were part of the research, 13 (56.5%) were female and 10 (43.5%) were male. The average age of the patients was determined to be 58.5, with a range of 29 to 84 and a median value of 60.

The stenosis rates detected in the first and second evaluations using both examination methods of the carotid arteries examined in the cases are shown in Tables 1 and 2, respectively.

When the cases with and without significant stenosis (over 50%) compared to NASCET in both ICAs in non-contrast MRA and DSA examinations are evaluated, the findings are shown in the tables below (Tables 3 and 4). The sensitivity was 78%, specificity 97%, positive predictive value 88%, negative predictive value 95%, and diagnostic accuracy 93% for detecting significant stenosis (>50%) of ICA for non-enhanced MRA examination according to the gold standard DSA.

When the cases with and without critical stenosis (over 70%) according to NASCET in both ICAs in non-contrast MRA and DSA examinations are evaluated, the findings are shown in the tables below (Tables 5 and 6). The sensitivity was 86%, specificity 100%, positive predictive value 100%, negative predictive value 98%, and diagnostic accuracy 98% for detecting critical stenosis (>70%) of ICA for non-enhanced MRA examination according to the gold standard DSA.

There was no significant stenosis in the right CCA and ECA, and there was 1 case with significant stenosis in the left CCA and ECA.

The agreement and kappa values between the results of the first and second evaluation of the carotid arteries according to the kappa agreement analysis are shown in the table below (Table 7). Accordingly, it was determined that the agreement between the 2 measurement sets was significant.

## DISCUSSION

Cerebrovascular events are a leading cause of mortality in developed nations. Ischemic strokes account for about 85% of all strokes. Extracranial carotid atherosclerosis accounts for 20% of these cases.<sup>7,8</sup> Given that atherosclerotic plaques in the extracranial carotid arteries are responsible for 25% of ischemic cerebrovascular events resulting in permanent neurological deficits, it is crucial to prioritize the treatment of these lesions.<sup>2</sup> Based on data from the Framingham heart study,<sup>9</sup> it was found that 7% of women and 9% of men aged 66-93 had carotid stenosis with a degree of more than 50%. Another study found that even carotid plaques that were subclinical and hemodynamically stable in individuals aged 45-64 were indicative of future cerebrovascular events. The NASCET study<sup>10</sup> found a correlation between the severity of stenosis and the likelihood of stroke development in symptomatic patients. The annual risk of ipsilateral stroke is 4.4% in cases where carotid stenosis is between 50 and 69% and the patient is treated conservatively. However, this risk increases to 13% in patients with stenosis above 70%. For patients without symptoms, the likelihood of having a stroke within a year is less than 1% when receiving aggressive medical treatment, provided that the narrowing of the blood vessels is greater than 50%. These studies indicate that it is necessary to use diagnostic methods to screen patients with risk factors for asymptomatic atherosclerotic carotid disease, as treatment can effectively reduce the risk of stroke. Therefore, by promptly identifying and treating the condition, the patient's yearly

**Table 1.** Right and Left CCA, ICA, ECA Stenosis Rates in First Measurement (%)

Patient No	Age/Gender	Right CCA		Right ICA		Right ECA		Left CCA		Left ICA		Left ECA	
		MRA	DSA	MRA	DSA	MRA	DSA	MRA	DSA	MRA	DSA	MRA	DSA
1	29/F	N	N	N	N	N	N	100	100	100	100	100	100
2	77/M	N	N	<50	<50	N	N	N	N	>70	>70	N	N
3	47/M	N	N	<50	N	N	N	N	N	<50	N	N	N
4	60/F	N	N	<50	50-69	<50	<50	N	N	100	100	<50	<50
5	80/F	N	N	N	N	N	N	N	N	N	N	N	N
6	34/M	N	N	<50	<50	N	N	N	N	<50	<50	N	N
7	70/F	N	N	N	N	N	N	N	N	<50	<50	N	N
8	66/M	<50	<50	<50	<50	<50	<50	<50	<50	50-69	<50	N	N
9	43/F	N	N	N	N	N	N	N	N	N	N	N	N
10	72/F	<50	<50	N	N	N	N	N	N	N	N	N	N
11	64/M	N	N	N	N	<50	<50	N	N	>70	>70	N	N
12	50/F	N	N	N	N	N	N	N	N	N	N	N	N
13	60/M	<50	<50	<50	50-69	N	N	<50	<50	N	N	N	N
14	70/M	N	N	<50	<50	N	N	N	N	>70	>70	N	N
15	44/F	N	N	N	N	N	N	N	N	N	N	N	N
16	50/F	N	N	N	N	N	N	N	N	N	N	N	N
17	84/M	N	N	>70	>70	N	N	<50	<50	<50	<50	<50	N
18	62/F	N	N	N	N	<50	<50	N	N	N	N	N	N
19	78/F	N	N	N	N	<50	50-69	<50	<50	N	N	N	N
20	52/M	N	N	N	N	N	N	N	N	N	N	N	N
21	50/F	N	N	N	N	N	N	N	N	N	N	N	N
22	34/F	N	N	N	N	N	N	N	N	N	N	N	N
23	70/M	N	N	50-69	>70	<50	<50	<50	<50	<50	<50	<50	<50

CCA, common carotid artery; ECA, external carotid artery; F, female; ICA, internal carotid artery; M, male.

Table 2. Right and Left CCA, ICA, ECA Stenosis Rates in Second Measurement (%)

Patient No	Age/Gender	Right CCA		Right ICA		Right ECA		Left CCA		Left ICA		Left ECA	
		MRA	DSA	MRA	DSA	MRA	DSA	MRA	DSA	MRA	DSA	MRA	DSA
1	29/F	N	N	N	N	N	N	100	100	100	100	100	100
2	77/M	N	N	<50	<50	N	N	N	N	>70	>70	N	N
3	47/M	N	N	N	N	N	N	N	N	N	N	N	N
4	60/F	N	N	<50	50-69	<50	<50	N	N	100	100	<50	<50
5	80/F	N	N	N	N	N	N	N	N	N	N	N	N
6	34/M	N	N	<50	<50	N	N	N	N	<50	<50	N	N
7	70/F	N	N	N	N	N	N	N	N	<50	<50	N	N
8	66/M	<50	<50	<50	<50	<50	<50	<50	<50	50-69	<50	N	N
9	43/F	N	N	N	N	N	N	N	N	N	N	N	N
10	72/F	<50	<50	N	N	N	N	N	N	N	N	N	N
11	64/M	N	N	N	N	<50	<50	N	N	>70	>70	N	N
12	50/F	N	N	N	N	N	N	N	N	N	N	N	N
13	60/M	<50	<50	<50	50-69	N	N	<50	<50	N	N	N	N
14	70/M	N	N	<50	<50	N	N	N	N	>70	>70	N	N
15	44/F	N	N	N	N	N	N	N	N	N	N	N	N
16	50/F	N	N	N	N	N	N	N	N	N	N	N	N
17	84/M	N	N	>70	>70	N	N	<50	<50	<50	<50	<50	N
18	62/F	N	N	N	N	<50	<50	N	N	N	N	N	N
19	78/F	N	N	N	N	<50	50-69	<50	<50	N	N	N	N
20	52/M	N	N	N	N	N	N	N	N	N	N	N	N
21	50/F	N	N	N	N	N	N	N	N	N	N	N	N
22	34/F	N	N	N	N	N	N	N	N	N	N	N	N
23	70/M	N	N	50-69	>70	<50	<50	<50	<50	<50	<50	<50	<50

CCA, common carotid artery; ECA, external carotid artery; F, female; ICA, internal carotid artery; M, male.

likelihood of experiencing a stroke can be diminished. Treatment options encompass surgical endarterectomy, percutaneous transluminal carotid angioplasty, and stenting, which is an interventional radiological procedure. Additionally, medical treatments targeting risk factors are also considered. Furthermore, obtaining precise and accurate measurements of the extent of stenosis is crucial in determining the most suitable course of treatment.<sup>11</sup> Medical treatment is adequate for stenosis below 50%. However, for stenosis ranging from 50% to 69%, it is recommended to undergo medical treatment and have follow-up appointments every 6 months. In cases where there is a narrowing of 70% or more in the carotid artery and the patient is experiencing symptoms, surgical endarterectomy or percutaneous transluminal carotid angioplasty and stenting procedures are performed (Figures 1-4). However, surgical treatment is not appropriate in cases of occlusion.<sup>12</sup>

Digital subtraction angiography is still considered the gold standard for imaging the carotid arteries. However, DSA, which is an invasive

method, has disadvantages such as containing ionizing radiation, the use of nephrotoxic agents, limited imaging projection, and a relatively high complication rate if not performed by qualified personnel. Embolism from a plaque potentially causing a cerebrovascular accident is one of its well-proven complications. The ACAS study reported a 1.2% risk of neurological deficit or death after DSA, while the NASCET study reported a 0.7% risk of permanent neurological deficit or death associated with selective angiography. The high complication rate limits its use as a screening test. In contrast, neither MRA nor CDUS carries the risk of complications at these rates. In addition, besides being noninvasive, they do not contain ionizing radiation. Currently, MRA imaging of the extracranial carotid arteries is mostly performed as contrast-enhanced angiography after the intravenous injection of gadolinium-based contrast agents. MR contrast agents have very few side effects, but they can cause nephrogenic systemic fibrosis in patients with renal failure. The fact that this possible side effect is now better known and the presence of patients who cannot receive contrast for other reasons has led to an increased

Table 3. Cases With and Without Significant Stenosis in MRA and DSA Examinations in the Right ICA

		DSA		Total
		There is Significant Narrowness	No Significant Narrowing	
MRA	There is significant narrowness	2	0	2
	No significant narrowing	2	19	21
	Total	4	19	23

DSA, digital subtraction angiography; ICA, internal carotid artery; MRA, magnetic resonance angiography.

Table 4. Cases With and Without Significant Stenosis in MRA and DSA Examinations in the Left ICA

		DSA		Total
		There is Significant Narrowness	No Significant Narrowing	
MRA	There is significant narrowness	5	1	6
	No significant narrowing	0	17	17
	Total	5	18	23

DSA, digital subtraction angiography; ICA, internal carotid artery; MRA, magnetic resonance angiography.

**Table 5.** Cases With and Without Critical Stenosis in MRA and DSA Examinations of the Right ICA

		DSA		Total
		There is Critical Stenosis	No Critical Stenosis	
MRA	There is critical stenosis	1	0	1
	No critical stenosis	1	21	22
	Total	2	21	23

DSA, digital subtraction angiography; ICA, internal carotid artery; MRA, magnetic resonance angiography.

interest in non-contrast MRA in recent years.<sup>4,13,14</sup> The most important difference of non-contrast MRA from RDUS, which is a cheaper and easily accessible noninvasive method, is that it is not user dependent. However, the most important disadvantage of TOF MRA, which is the most widely used non-contrast MRA method in carotid artery imaging today, is signal loss. Signal loss occurs due to the phase shift that develops due to the disruption of normal laminar flow in the vessel (turbulent flow pattern occurs near the stenotic plaque) and overstates the existing stenosis.<sup>15,16</sup> This may lead to incorrect diagnosis and treatment of the patient. In one of our patients in this study, left ICA stenosis was overestimated with TOF MRA, and the stenosis rate of less than 50% was measured between 50 and 69%. In addition, right ICA stenosis was underestimated by TOF MRA in 3 of our patients. While stenosis was between 50 and 69% in 2 of them, it was measured as less than 50%, and in one of them, the true stenosis rate was measured between 50 and 69%. In the last case, if the patient had not undergone DSA examination, surgical or interventional radiological treatment, which was actually indicated, would have been delayed.

In order for non-contrast MRA to be a diagnostic test that can be used in screening, the sensitivity, specificity rates, and positive and negative predictive values in detecting pathology should be known and at an acceptable level.

Chappell et al<sup>13</sup> stated that noninvasive test combinations do not increase sensitivity and specificity but increase the cost. The sensitivity values of all modalities in detecting stenosis between 50 and 69% were found to be significantly lower than their sensitivities in detecting stenosis between 70 and 99%. Therefore, they emphasized that it is difficult to detect moderate (50-69%) stenosis (since all modalities have low sensitivity values), but their diagnosis is important (because some patients in this group benefit from carotid endarterectomy). In our study, it was observed that the sensitivity and specificity values, which were found to be higher in stenosis above 70%, were consistent with the literature.

**Table 6.** Cases With and Without Critical Stenosis on MRA and DSA Examinations of the Left ICA

		DSA		Total
		There is Critical Stenosis	No Critical Stenosis	
MRA	There is critical stenosis	5	0	5
	No critical stenosis	0	18	18
	Total	5	18	23

DSA, digital subtraction angiography; ICA, internal carotid artery; MRA, magnetic resonance angiography.

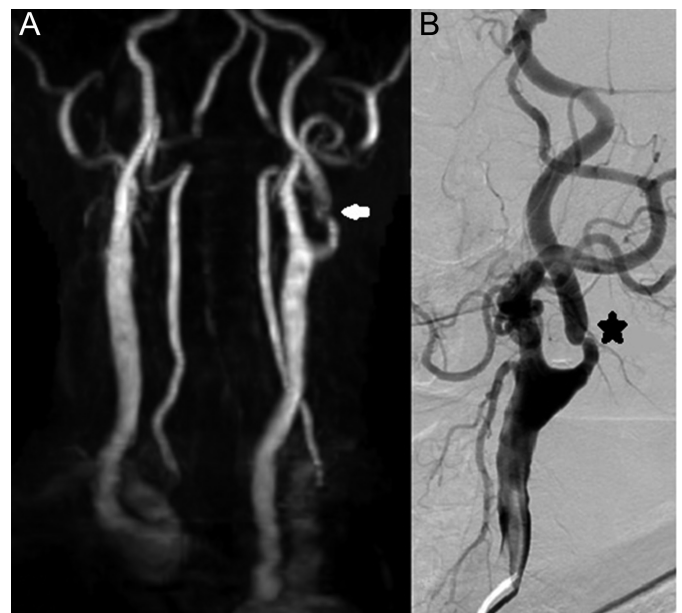
**Table 7.** According to Kappa Analysis, Agreement Between the Results of the First and Second Evaluation of the Carotid Arteries and Kappa Values

Carotid Artery	Kappa Value	P
Right CCA	1.000	<.001
Right ICA	0.916	<.001
Right ECA	1.000	<.001
Left CCA	1.000	<.001
Left ICA	0.916	<.001
Left ECA	1.000	<.001

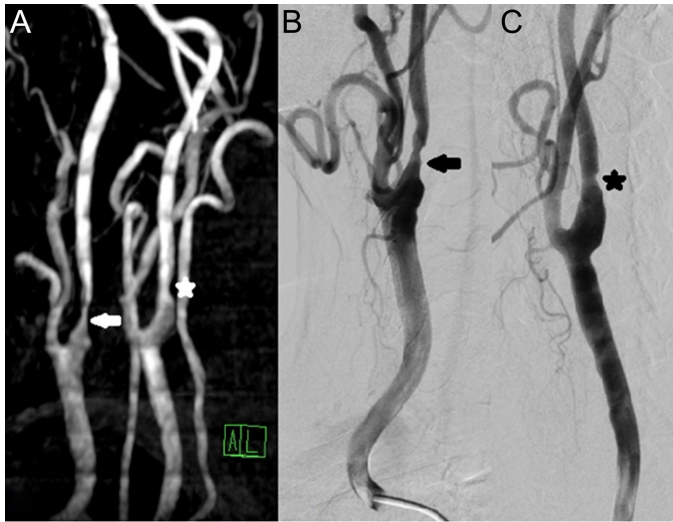
CCA, common carotid artery; ECA, external carotid artery; ICA, internal carotid artery.

Wardlaw et al<sup>14</sup> stated that the sensitivity of non-contrast MRA was 88% and the specificity was 84% in cases of critical stenosis of 70% and above. In stenosis of 50%-69%, the sensitivity of non-contrast MRA was 37%, and the specificity was 91%. In our study, the sensitivity was 86% and the specificity was 100% in detecting critical stenosis (>70%) of the ICA for non-contrast MRA examination. At this point, although our sensitivity values were similar to those in the study by Chappell et al and Wardlaw et al, our specificity values were slightly higher.

The utilization of a 3 T MRI system to acquire the majority of our 3D TOF MRA images represents a noteworthy advantage in our study. The limitations commonly discussed in the literature regarding 1.5 T MRI systems have been mostly eliminated. 3D TOF MRA benefits at 3 T MRI systems from both an improved signal-to-noise ratio (SNR) and longer T1 relaxation times in the cerebral parenchyma. This leads to enhanced saturation of stationary spins and improved contrast between



**Figure 1.** A 64-year-old male patient. He was admitted to our hospital with the complaint of abrupt onset of right upper and lower extremity weakness 3 months ago. He has a history of surgery due to hypertension, diabetes, and nephrolithiasis, and his creatinine value was found to be 1.4 in laboratory tests. The patient underwent carotid and vertebral artery RDUS, neck TOF MRA, and carotid DSA procedures in our unit, and then the patient was treated endovascularly. (A) A critical stenosis of over 70% is seen in the left ICA in the TOF MRA coronal MIP image (white arrow). (B) On DSA examination, more than 70% critical stenosis is observed in the left proximal ICA (black star).



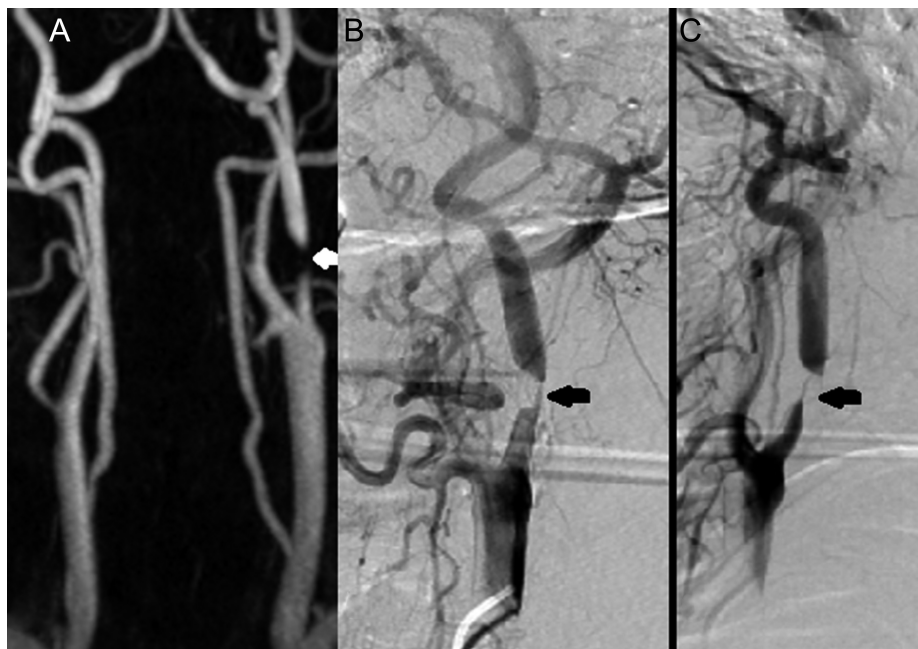**Figure 2.** An 84-year-old male patient. He was admitted to our hospital with the complaint of weakness in the left upper extremity that developed 1 week ago. He has a history of hypertension, smoking, and an operation due to benign prostatic hyperplasia, and creatinine value was found to be 1.2 in laboratory tests. The patient underwent neck TOF MRA, and carotid DSA procedures in our unit. (A) On TOF MRA coronal-oblique MIP image, critical stenosis of over 70% (white arrow) in the right ICA and less than 50% stenosis in the left ICA (white star). (B) A critical stenosis of over 70% is observed in the proximal right ICA on DSA examination (black arrow). (C) Less than 50% stenosis is observed in the proximal left ICA on DSA examination (black star).

vessels and the background. High-spatial-resolution TOF MRA at 3.0-T systems offers improved capacity for diagnosis to investigate cerebrovascular disease.<sup>17,18</sup> In our study, we aimed to compare the results of

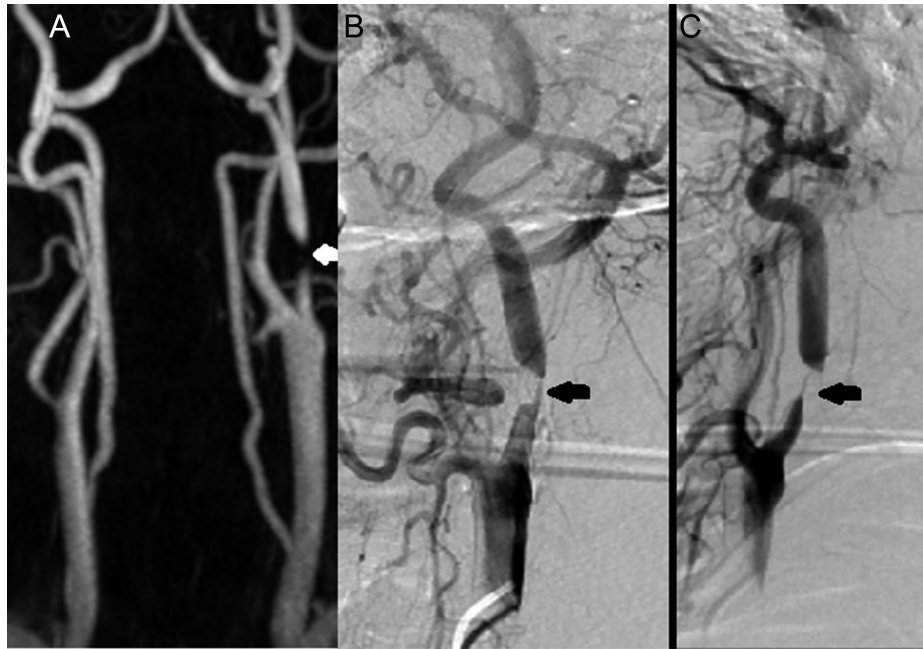
TOF MRA obtained from 3.0 T MRI and 1.5 T MRI systems. However, due to the insufficient number of patients in our study, we were unable to establish a statistically significant comparison. Therefore, we plan to conduct more comprehensive studies in the future to make this comparison.

We hope that our study will contribute to further research on comparisons between non-contrast MRA and DSA, which are used as imaging modalities to determine the treatment and prognosis of atherosclerotic carotid artery diseases.

There are limitations when assessing vascular structures in TOF MRA. Initially, it is important to note that patient movement, particularly during activities such as swallowing and pulsation, can have a detrimental effect on the quality of MRI images. Another issue arises in situations that disrupt the laminar flow of blood. After a severe obstruction in the blood vessel, the flow of blood becomes turbulent instead of laminar, resulting in a “signal void.” Due to the possibility of a signal void appearing in both cases of true complete occlusion and slow blood flow distal to severe stenosis, TOF MRA is not a dependable method for distinguishing between these 2 conditions. A further limitation arises from the signal void caused by the ‘in-plane’ flow that takes place in tortuous blood vessels that are not perpendicular to the imaging plane. In this situation, the extent of stenosis can be overestimated. Our study did not include any patients with tortuous carotid vascular structures. Obtaining the most precise outcome can potentially be achieved by conducting measurements in various planes. A comparable issue can arise during CDUS examinations when assessing tortuous vessels. Tortuous vessels without stenosis exhibit a notable rise in peak systolic velocities.<sup>16,19</sup> Although there are several limitations, the ability to combine TOF MRA with CDUS is a significant advantage, particularly for patients with renal failure or an allergy to contrast material.



**Figure 3.** A 70-year-old male patient. He was admitted to our hospital with the complaint of dizziness. While investigating the etiology of vertigo, carotid stenosis was detected in CDUS. In laboratory tests, the creatinine value was found to be 1.2. The patient underwent neck TOF MRA, and carotid DSA procedures in our unit. (A–B) TOF MRA sagittal-oblique MIP images show 50%-69% stenosis (white arrows) in the right ICA proximal part and less than 50% stenosis (white stars) in the left ICA proximal. (C) On DSA examination, a critical stenosis of over 70% is observed in the right proximal ICA (black arrow). (D) In DSA examination, less than 50% stenosis is detected in the left proximal ICA (black star).



**Figure 4.** A 70-year-old male patient. He was examined in our hospital for right hemiparesis. He has a history of hypertension and diabetes, and a creatinine value of 1.3 in laboratory tests. The patient underwent neck TOF MRA, and carotid DSA procedures in our unit. (A) TOF MRA coronal-oblique MIP images show near-total critical stenosis in the left ICA proximal part (white arrow). (B–C) In DSA examination, near-total critical stenosis is observed in the proximal left ICA on anterior-posterior and lateral views (black arrows).

The biggest reason for these discrepancies is the low number of patients and the low rate of patients with significant stenosis, which are the most important limitations of our retrospective study. This reduces statistical significance and causes “selection” BIAS. Nevertheless, despite the limited sample size, we are still eager to present the significant findings from this study as a preliminary report to the literature. In addition, we could not determine the efficacy of non-contrast MRA in imaging these arteries, as there were not enough patients with critical stenosis in CCA and ECA. Another limitation is that we did not compare the non-contrast MRA findings with 3D rotational DSA images.

## CONCLUSION

Non-contrast MRA, which does not contain ionizing radiation and does not require nephrotoxic agents in patients with impaired renal function, can be used as an additional imaging method in cases where CDUS is insufficient in imaging the carotid arteries. Sometimes, it can be used safely in combination with CDUS to increase the accuracy of diagnosis with high sensitivity and specificity.

**Ethics Committee Approval:** Ethical committee approval was received from Ankara University Faculty of Medicine Clinical Research Ethics Committee (Date: 2014; Decision No: 06-355-18).

**Informed Consent:** Written informed consent was obtained from the patients who agreed to take part in the study.

**Peer-review:** Externally peer-reviewed.

**Author Contributions:** Concept – K.B.M.; Design – A.O.G.; Supervision – K.B.M., U.S.; Resources – K.B.M., A.O.G.; Materials – K.B.M., A.O.G.; Data Collection and/or Processing – K.B.M.; Analysis and/or Interpretation – K.B.M., U.S.; Literature Search – K.B.M., A.O.G.; Writing Manuscript – K.B.M., A.O.G.; Critical Review – K.B.M., U.S.

**Declaration of Interests:** The authors have no conflict of interest to declare.

**Funding:** The authors declared that this study has received no financial support.

## REFERENCES

1. Paraskevas KI, Mikhailidis DP, Antignani PL, et al. Comparison of recent practice guidelines for the management of patients with asymptomatic carotid stenosis. *Angiology*. 2022;73(10):903-910. [\[CrossRef\]](#)
2. Atman D, Üstüner E, Uzun E, et al. Klinik olarak anlamlı Karotis Arter Stenozlarının Değerlendirilmesinde renkli Doppler Görüntüleme, manyetik rezonans anjiyografi ve dijital Subtraksiyon anjiyografi Yöntemlerinin Karşılaştırılması. *Ank Univ Tıp Fak Mecmuası*. 2014;67(1):5-16. [\[CrossRef\]](#)
3. Heck D, Jost A. Carotid stenosis, stroke, and carotid artery revascularization. *Prog Cardiovasc Dis*. 2021;65:49-54. [\[CrossRef\]](#)
4. Platzek I, Sieron D, Wiggermann P, Laniado M. Carotid artery stenosis: comparison of 3D time-of-flight MR angiography and contrast-enhanced MR angiography at 3T. *Rad Res Pract*. 2014;2014:508715. [\[CrossRef\]](#)
5. Barlinn K, Alexandrov AV. Vascular imaging in stroke: comparative analysis. *Neurotherapeutics*. 2011;8(3):340-348. [\[CrossRef\]](#)
6. Gupta A, Baradaran H, Kamel H, et al. Intraplaque high-intensity signal on 3D time-of-flight MR angiography is strongly associated with symptomatic carotid artery stenosis. *AJNR Am J Neuroradiol*. 2014;35(3):557-561. [\[CrossRef\]](#)
7. Coşkun FY, Yüce M, Özer HO. İnme nedeni olarak Aterosklerotik Karotis Arter hastalığı: risk Faktörlerinin Kontrolünde Medikal yaklaşım. *Türk Klin J Radiol-Spec Top*. 2014;7(3):6-11.
8. Temizöz O, Nayman A, Koç O, Hastalığı AKA. Tanıda dijital çıkartma Anjiyografisi. *Türk Klin J Radiol-Spec Top*. 2014;7(3):45-49.
9. Romero JR, Beiser A, Seshadri S, et al. Carotid artery atherosclerosis, MRI indices of brain ischemia, aging, and cognitive impairment: the Framingham study. *Stroke*. 2009;40(5):1590-1596. [\[CrossRef\]](#)
10. Hathout GM, Fink JR, El-Saden SM, Grant EG. Sonographic NASCET index: a new doppler parameter for assessment of internal carotid artery stenosis. *AJNR Am J Neuroradiol*. 2005;26(1):68-75.
11. Adla T, Adlova R. Multimodality imaging of carotid stenosis. *Int J Angiol*. 2015;24(3):179-184. [\[CrossRef\]](#)
12. Dikici AS, Bakan S, Kantarcı F, Hastalığı AKA. Tanıda Doppler Ultrasonografi. *Türk Klin J Radiol-Spec Top*. 2014;7(3):28-32.

13. Chappell FM, Wardlaw JM, Young GR, et al. Carotid artery stenosis: accuracy of noninvasive tests—individual patient data meta-analysis. *Radiology*. 2009;251(2):493-502. [\[CrossRef\]](#)
14. Wardlaw JM, Chappell FM, Best JJK, Wartolowska K, Berry E, National Health Service Research and Development Health Technology Assessment Carotid Stenosis Imaging Group. Non-invasive imaging compared with intra-arterial angiography in the diagnosis of symptomatic carotid stenosis: a meta-analysis. *Lancet*. 2006;367(9521):1503-1512. [\[CrossRef\]](#)
15. Nederkoorn PJ, van der Graaf Y, Eikelboom BC, van der Lugt A, Bartels LW, Mali WPTM. Time-of-flight MR angiography of carotid artery stenosis: does a flow void represent severe stenosis? *AJNR Am J Neuroradiol*. 2002;23(10):1779-1784.
16. Jaff MR, Goldmakher GV, Lev MH, Romero JM. Imaging of the carotid arteries: the role of duplex ultrasonography, magnetic resonance arteriography, and computerized tomographic arteriography. *Vasc Med*. 2008;13(4):281-292. [\[CrossRef\]](#)
17. Graves MJ. 3 T: the good, the bad and the ugly. *Br J Radiol*. 2022;95(1130):20210708. [\[CrossRef\]](#)
18. Willinek WA, Born M, Simon B, et al. Time-of-flight MR angiography: comparison of 3.0-T imaging and 1.5-T imaging--initial experience. *Radiology*. 2003;229(3):913-920. [\[CrossRef\]](#)
19. Capel KW, Roberts G, Kurer AD, et al. Beyond TOF MRA: review of flow imaging techniques. *Neurographics*. 2023;13(4):294-314. [\[CrossRef\]](#)