

# Normal Achilles Tendon Morphology: A Radioanatomical Study

Taner Kösetürk<sup>1</sup> , Mukadder Sunar<sup>1</sup> , Ömer Kazcı<sup>2</sup> , Özlem Çelik Aydın<sup>3</sup> 

<sup>1</sup>Department of Anatomy, Erzincan Binali Yıldırım University, Mengücek Gazi Training and Research Hospital, Erzincan, Turkey

<sup>2</sup>Department of Radiology, Ankara Training and Research Hospital, Ankara, Turkey

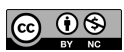
<sup>3</sup>Department of Medical Pharmacology, Erzincan Binali Yıldırım University, Mengücek Gazi Training and Research Hospital, Erzincan, Turkey

**Cite this article as:** Kösetürk T, Sunar M, Kazcı Ö, Çelik Aydın Ö. Normal achilles tendon morphology: A radioanatomical study. *Current Research in MRI*, 2023;2(2):32-35.

**Corresponding author:** Taner Kösetürk, e-mail: tanerkoseturk@gmail.com

**Received:** June 02, 2023 **Accepted:** July 10, 2023 **Publication Date:** August 19, 2023

DOI:10.5152/CurrResMRI.2023.23063



Content of this journal is licensed under a Creative Commons Attribution-NonCommercial 4.0 International License.

## Abstract

**Objective:** The evaluation of the morphometric features of the Achilles tendon with magnetic resonance imaging is an essential aspect of musculoskeletal imaging, with significant implications for the diagnosis and management of Achilles tendon injuries. The aim of this study is to investigate the morphology of the Achilles tendon in normal and healthy individuals and establish a standard value using specific measurement techniques.

**Methods:** The sagittal images were used to compute the free Achilles tendon length between the most distal portion of the soleus muscle fibers and the proximal-superior calcaneal insertion of the Achilles tendon. On the axial images, the most distal portion of the soleus muscle fibers was identified, and the free Achilles tendon length was measured between this location and the Achilles tendon's most distal calcaneal insertion. In the axial section, the thickest portion of the unrestricted portion of the Achilles tendon in the anteroposterior plane was measured. The distance between the point at which the Achilles tendon attained its maximum thickness and its proximal insertion into the calcaneus was measured.

**Results:** The thickest portion of the unconstrained portion of the Achilles tendon, known as the APM distance, was measured to be  $5 \pm 0.2$  mm in the anteroposterior plane. The MKPM distance, which is the distance from the point where the Achilles tendon reaches its maximal thickness to the proximal insertion of the calcaneus, was measured to be  $18.4 \pm 4.7$  mm.

**Conclusion:** Future research should aim to expand our understanding of the factors influencing Achilles tendon morphology and their impact on tendon health and injury risk. Such knowledge can inform the development of personalized strategies for the prevention, diagnosis, and treatment of Achilles tendon disorders.

**Keywords:** Tendons, radiology, muscles

## INTRODUCTION

The Achilles tendon, the most substantial tendon in the human body, is critical to mobility due to its role in enabling walking, running, and jumping.<sup>1</sup> However, it is also one of the most frequently injured tendons, with approximately 5%-12% of all athletes experiencing Achilles tendon injuries in their lifetimes.<sup>2</sup> These injuries not only disrupt an individual's daily life and athletic performance but may also necessitate lengthy recovery periods or surgical intervention in severe cases.<sup>3</sup>

Magnetic resonance imaging (MRI) has become a pivotal tool for the clinical assessment of Achilles tendon pathology. It provides a comprehensive assessment of the tendon's structural and morphological features, identifying injuries or pathological changes that may not be discernible with physical examination alone.<sup>4</sup> Nevertheless, the utilization of MRI in this context is predicated on a nuanced understanding of the normal morphology and variations within the general population. This understanding can aid clinicians in differentiating normal anatomical variations from pathological deviations, which is essential for accurate diagnosis and effective therapeutic intervention.

Several studies have elucidated the normal morphological characteristics of the Achilles tendon. The Achilles tendon, a fibrous structure formed from the confluence of the gastrocnemius and soleus muscles, has an average length of 15 cm in adults, with a broadest cross-sectional area at about 4 cm from the tendon's insertion onto the calcaneus.<sup>5</sup> However, the Achilles tendon demonstrates substantial inter-individual variability in its morphometric features, including length, width, and thickness. The reasons behind these variations are multifactorial and likely include age, gender, physical activity level, and genetic predisposition.<sup>6</sup>

In order to interpret MRI images of the Achilles tendon accurately, it is crucial to appreciate not only its typical morphometric features but also the normal variations that may occur. For instance, recent research using MRI revealed that the cross-sectional area of the Achilles tendon tends to decrease with age, suggesting age-specific reference values may be beneficial for optimal interpretation. Similarly, gender-specific differences in Achilles tendon morphology have been reported, with men generally having larger and longer tendons than women.<sup>7</sup> These findings underscore the importance of taking individual patient characteristics into account when evaluating Achilles tendon images.

Assessment of the morphometric features of the Achilles tendon via MRI has significant implications for the management of Achilles tendon injuries. Understanding the normal Achilles tendon morphology can aid in identifying pathological changes that may contribute to the risk of injury, such as tendon thickening, which is commonly observed in tendinopathy.<sup>8</sup> Moreover, it can inform the design and application of surgical procedures for Achilles tendon repair, potentially improving patient outcomes.<sup>9</sup>

The evaluation of the morphometric features of the Achilles tendon with MRI is an essential aspect of musculoskeletal imaging, with significant implications for the diagnosis and management of Achilles tendon injuries. The aim of this study is to investigate the morphology of the Achilles tendon in normal and healthy individuals and establish a standard value using specific measurement techniques.

## METHODS

The Clinical Research Ethics Committee of Erzincan Binali Yildirim University approved this study (Date: February 21, 2022, Number: 15/19) and the patients gave their written consent. Examining ankle MRI scans from the years 2019 to 2023, data relevant to 342 patients were retrospectively collected from the Department of Radiology, Erzincan Binali Yildirim University Faculty of Medicine. Excluded from the study were patients with Achilles tendon rupture, diseases affecting the anatomy and physiology of the musculoskeletal system (such as cancer and soft tissue infections), patients who underwent ankle surgery, patients with calcaneal fractures, and patients unable to obtain suitable images due to orthopedic equipment or movement-related artifacts. Only patients with high-quality anatomical and pathophysiological images of the musculoskeletal system were included in the study.

This manuscript adheres to the applicable STROBE guidelines.

Using 18-channel coils on a 1.5T power 32-channel MRI device (Siemens magnetom aera, Erlangen, Germany), ankle imaging was performed. Using the Siemens Somatom Sensation-Syngo.via software (Siemens Healthineers, Erlangen, Germany), images from the Picture Archiving Communication System archive were analyzed.

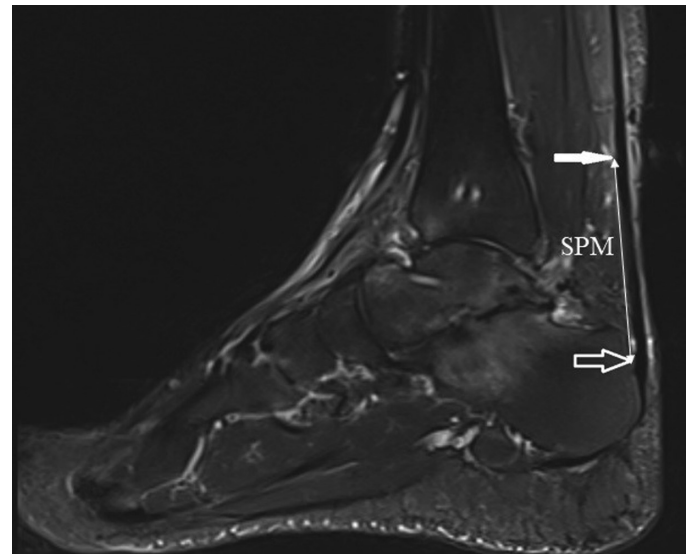
The T1-weighted sequences in the coronal and sagittal planes, T2-weighted sequences in the axial and sagittal planes, and Proton density (PD)-weighted fat-suppressed sequences in the axial and coronal planes were performed on all patients. The PD-weighted turbo spin echo (TSE) with echo time (TE) of 21 ms and repetition time (TR) of 2400 ms, T2-weighted (TSE) with TE of 56 ms and TR of 3920 ms, and T1-weighted with TE of 10 ms and TR of 797 ms were the most frequently used protocols. The field of view was 200 mm and voxel size was  $0.80 \times 0.83.5$  mm. Section thickness was 4 mm.

## MAIN POINTS

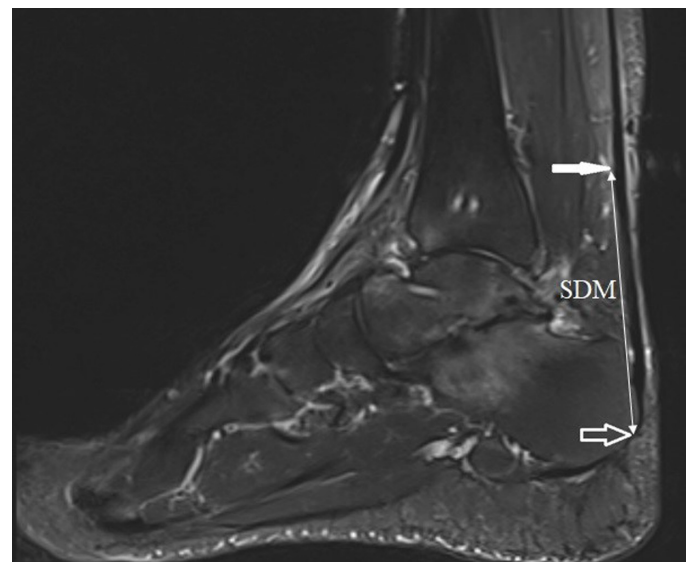
- The morphometric characteristics of the Achilles tendon, such as length, thickness, and cross-sectional area, are critical to its functionality and can be precisely assessed by magnetic resonance imaging.
- The morphometric properties of the Achilles tendon vary significantly in the general population, underscoring the significance of personalized examinations in clinical practice.
- The morphological properties of the Achilles tendon are influenced by age, gender, and physical activity level, and understanding these aspects can aid in the prevention, diagnosis, and treatment of Achilles tendon problems.

The sagittal images were used to compute the free Achilles tendon length between the most distal portion of the soleus muscle fibers and the proximal-superior calcaneal insertion of the Achilles tendon (SPM) (Figure 1). On the axial images, the most distal portion of the soleus muscle fibers was identified, and the free Achilles tendon length was measured between this location and the Achilles tendon's most distal calcaneal insertion.

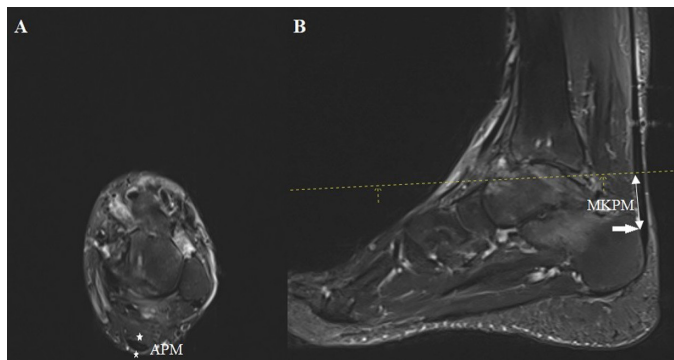
In the axial section, the thickest portion of the unrestricted portion of the Achilles tendon in the anteroposterior plane was measured. Figure 2 depicts sagittal sections used to confirm this measurement (APM).



**Figure 1.** T2 fat-suppressed sequence showing the Achilles tendon, showing the most distal part of the soleus muscle (solid white arrow) and the most proximal anterior calcaneal insertion of the Achilles tendon (hollow white arrow). The distance between the 2 arrows is defined as the SPM distance.



**Figure 2.** T2 fat-suppressed sequence showing the Achilles tendon, showing the most distal part of the soleus muscle (solid white arrow) and the most distal calcaneal insertion of the Achilles tendon (hollow white arrow). The distance between the 2 arrows is defined as the SDM distance.



**Figure 3.** Axial (A) and sagittal (B) sections of the Achilles tendon in T2 fat-suppressed sequence. The thickest part of the Achilles tendon in the axial sections (the distance between the two white stars) was determined, and the anteroposterior thickness of the tendon at this level was defined as the APM distance. In addition, this level was determined in sagittal sections (dashed yellow line), and the distance from the point determined in sagittal sections to the calcaneus antero-proximal insertion of the Achilles tendon (solid white arrow) was defined as the MKPM distance.

The distance between the point at which the Achilles tendon attained its maximum thickness and its proximal insertion into the calcaneus was measured (MKPM) (Figure 3).

You can find STROBE Statement in the Appendix.

### Statistical Analysis

Data were analyzed using the IBM Statistical Package for Social Sciences v25 for Windows (IBM SPSS Inc., Chicago, Ill, USA). The normal distribution of the data was evaluated with the Kolmogorov–Smirnov test. Numerical variables with normal distribution were shown as mean  $\pm$  SD. Categorical variables were shown as numbers and percentages. For the comparison of numerical variables between the 2 groups, Student's *t*-test was used.

A 2-tailed value of  $P < .05$  was considered statistically significant.

### RESULTS

In our investigation, we retrospectively examined 342 MRI images devoid of Achilles tendon pathology. There were 174 males and 168 females in the examined images, with a mean age of  $36.6 \pm 13.2$  (18–75) years. The distance between the most distal portion of the soleus muscle fibers and the proximal-superior calcaneal insertion of the Achilles tendon, known as the SPM distance (value range 6.7–69.3 mm), was measured to be  $38.9 \pm 13.8$  mm in the healthy population. The length of the free Achilles tendon between the most distal segment of the soleus muscle fibers and the distal calcaneal insertion of the Achilles tendon was measured to be  $59.3 \pm 11.4$  mm (value range: 27–91.9 mm).

The thickest portion of the unconstrained portion of the Achilles tendon, known as the APM distance, was measured to be  $5 \pm 0.2$  mm (value range: 3.8–5.9 mm) in the anteroposterior plane.

The MKPM distance, which is the distance from the point where the Achilles tendon reaches its maximal thickness to the proximal insertion of the calcaneus, was measured to be  $18.4 \pm 4.7$  mm (value range: 3.8–21.9 mm).

The ratio of the maximal tendon thickness to the proximal calcaneal insertion, termed MKPM/SPM, was  $49.6 \pm 17.2\%$  (value range:

**Table 1.** Patient Values Measured by Age and Gender and Their Comparison

Distances	Mean (mm)	Male (mm)	Female (mm)	<i>P</i> ( <i>t</i> -Tests)
SPM	$38.9 \pm 13.8$	$41.6 \pm 13.6$	$36.3 \pm 12.6$	$>.05$
SDM	$59.3 \pm 11.4$	$63.8 \pm 11.9$	$53 \pm 12.6$	$>.05$
APM	$5 \pm 0.2$	$5.1 \pm 0.1$	$4.3 \pm 0.7$	.002
MKPM	$18.4 \pm 4.7$	$19.1 \pm 3.4$	$16.5 \pm 4.0$	.005
MKPM/SPM (percent)	$49.6 \pm 19.5$	$48.1 \pm 18.7$	$48.6 \pm 15.2$	$>.05$

15.9–0.98 mm) (Table 1). Men had a greater APM distance and MKPM distance to the calcaneal insertion than women (Table 1). There was no other difference between the sexes in the measurements.

### DISCUSSION

The morphometric features of the Achilles tendon have become a focal point of research given their fundamental role in diagnosing and managing tendon disorders. In this discussion, we will review these features in the context of recent studies and their implications for our understanding of Achilles tendon health and disease.

The Achilles tendon's morphological characteristics, including length, thickness, and cross-sectional area, play a vital role in its functionality.<sup>10</sup> These features, which can be accurately measured via MRI, reflect the tendon's mechanical properties and its ability to transmit forces from the calf muscles to the foot. As such, deviations from the normal morphology can adversely affect these functions and potentially increase the risk of injury.

Recent MRI studies have shed light on the variability of Achilles tendon morphometric features within the general population. For instance, Szaro et al<sup>5</sup> found a substantial range in the cross-sectional area and thickness of the Achilles tendon in their cohort of healthy adults, highlighting the importance of individualized assessments in clinical practice. These findings echo earlier studies that demonstrated significant variations in Achilles tendon morphology and suggested that these differences might be related to factors such as age, sex, and physical activity level.<sup>11</sup>

Age-related changes in Achilles tendon morphology are particularly noteworthy. As the cross-sectional area is a determinant of tendon strength, age-related decreases could potentially contribute to the higher incidence of Achilles tendon injuries observed in older adults. Consequently, the application of age-specific reference values in clinical practice may facilitate earlier identification of individuals at risk and promote preventive measures.

Similarly, gender differences in Achilles tendon morphometry have been reported, with men generally having larger tendons than women.<sup>11</sup> These findings could partly explain the higher incidence of Achilles tendon injuries in men compared to women and emphasize the need for gender-specific reference values in the clinical interpretation of Achilles tendon MRI images.

The morphometric features of the Achilles tendon are also thought to be influenced by physical activity level. Several studies have shown that regular physical activity can lead to adaptations in the Achilles tendon, such as increased thickness and cross-sectional area, which may enhance the tendon's ability to withstand mechanical loads.<sup>12</sup> However, excessive or inappropriate loading, as often seen in high-level sports, can induce pathological changes in the tendon, including thickening

and disorganized collagen structure.<sup>8</sup> Therefore, in athletes and highly active individuals, careful interpretation of MRI images is necessary to differentiate normal adaptations from pathological changes.

Our study differs from other studies in the literature in several ways. First, we had a larger reservoir of data than those in the literature. On the analyzed images, measurements of the normal tendon were recorded using a variety of techniques, and a standard value was sought. By reference to these values, the values above and below the defined values may support pathology.

Our work is subject to certain restrictions. One health facility has been utilized. Unfortunately, diversity is lacking. It is a limitation that the quantity of data is not greater.

In conclusion, the evaluation of the morphometric features of the Achilles tendon with MRI offers valuable insights into the health and function of this critical structure. Future research should aim to expand our understanding of the factors influencing Achilles tendon morphology and their impact on tendon health and injury risk. Such knowledge can inform the development of personalized strategies for the prevention, diagnosis, and treatment of Achilles tendon disorders.

**Ethics Committee Approval:** Ethics committee approval was received for this study from the ethics committee of Erzincan Binali Yıldırım University (Date: February 21, 2022, Number: 15/19).

**Informed Consent:** Informed consent is waived as a result of retrospective nature.

**Peer-review:** Externally peer-reviewed.

**Author Contributions:** Concept – T.K., M.S.; Design – T.K.; Supervision – T.K.; Resources – M.S.; Materials – Ö.K.; Data Collection and/or Processing – Ö.K.; Analysis and/or Interpretation – T.K.; Literature Search – Ö.A.; Writing Manuscript – T.K.; Critical Review – Ö.A.

**Declaration of Interests:** The authors declare that they have no competing interest.

**Funding:** The authors declared that this study has received no financial support.

## REFERENCES

1. Bossley CJ. Rupture of the Achilles tendon. *J Bone Joint Surg Am.* 2000;82(12):1804. [\[CrossRef\]](#)
2. de Jonge S, van den Berg C, de Vos RJ, et al. Incidence of midportion Achilles tendinopathy in the general population. *Br J Sports Med.* 2011;45(13):1026-1028. [\[CrossRef\]](#)
3. Khan KM, Forster BB, Robinson J, et al. Are ultrasound and magnetic resonance imaging of value in assessment of Achilles tendon disorders? A two year prospective study. *Br J Sports Med.* 2003;37(2):149-153. [\[CrossRef\]](#)
4. Khan KM, Cook JL, Bonar F, Harcourt P, Astrom M. Histopathology of common tendinopathies. Update and implications for clinical management. *Sports Med.* 1999;27(6):393-408. [\[CrossRef\]](#)
5. Szaro P, Witkowski G, Smigielski R, Krajewski P, Ciszek B. Fascicles of the adult human Achilles tendon - an anatomical study. *Ann Anat.* 2009;191(6):586-593. [\[CrossRef\]](#)
6. Kannus P. Structure of the tendon connective tissue. *Scand J Med Sci Sports.* 2000;10(6):312-320. [\[CrossRef\]](#)
7. Magnusson SP, Narici MV, Maganaris CN, Kjaer M. Human tendon behaviour and adaptation, in vivo. *J Physiol.* 2008;586(1):71-81. [\[CrossRef\]](#)
8. Cook JL, Khan KM, Harcourt PR, Grant M, Young DA, Bonar SF. A cross sectional study of 100 athletes with jumper's knee managed conservatively and surgically. The Victorian Institute of Sport tendon study group. *Br J Sports Med.* 1997;31(4):332-336. [\[CrossRef\]](#)
9. Lee SJ, Aadalén KJ, Malaviya P, et al. Tibiofemoral contact mechanics after serial medial meniscectomies in the human cadaveric knee. *Am J Sports Med.* 2006;34(8):1334-1344. [\[CrossRef\]](#)
10. Lee SS, Piazza SJ. Built for speed: musculoskeletal structure and sprinting ability. *J Exp Biol.* 2009;212(22):3700-3707. [\[CrossRef\]](#)
11. Magnusson SP, Kjaer M. Region-specific differences in Achilles tendon cross-sectional area in runners and non-runners. *Eur J Appl Physiol.* 2003;90(5-6):549-553. [\[CrossRef\]](#)
12. Kongsgaard M, Reitelseder S, Pedersen TG, et al. Region specific patellar tendon hypertrophy in humans following resistance training. *Acta Physiol (Oxf).* 2007;191(2):111-121. [\[CrossRef\]](#)



## APPENDIX. STROBE STATEMENT—CHECKLIST OF ITEMS THAT SHOULD BE INCLUDED IN REPORTS OF OBSERVATIONAL STUDIES

	Item No	Recommendation
Title and abstract	1	(a) Indicate the study's design with a commonly used term in the title or the abstract (b) Provide in the abstract an informative and balanced summary of what was done and what was found
Introduction		
Background/rationale	2	Explain the scientific background and rationale for the investigation being reported
Objectives	3	State specific objectives, including any prespecified hypotheses
Methods		
Study design	4	Present key elements of study design early in the paper
Setting	5	Describe the setting, locations, and relevant dates, including periods of recruitment, exposure, follow-up, and data collection
Participants	6	(a) <i>Cohort study</i> —Give the eligibility criteria, and the sources and methods of selection of participants. Describe methods of follow-up <i>Case-control study</i> —Give the eligibility criteria and the sources and methods of case ascertainment and control selection. Give the rationale for the choice of cases and controls <i>Cross-sectional study</i> —Give the eligibility criteria and the sources and methods of selection of participants (b) <i>Cohort study</i> —For matched studies, give matching criteria and number of exposed and unexposed <i>Case-control study</i> —For matched studies, give matching criteria and the number of controls per case
Variables	7	Clearly define all outcomes, exposures, predictors, potential confounders, and effect modifiers. Give diagnostic criteria, if applicable
Data sources/ measurement	8*	For each variable of interest, give sources of data and details of methods of assessment (measurement). Describe the comparability of assessment methods if there is more than 1 group
Bias	9	Describe any efforts to address potential sources of bias
Study size	10	Explain how the study size was arrived at
Quantitative variables	11	Explain how quantitative variables were handled in the analyses. If applicable, describe which groupings were chosen and why
Statistical methods	12	(a) Describe all statistical methods, including those used to control for confounding (b) Describe any methods used to examine subgroups and interactions (c) Explain how missing data were addressed (d) <i>Cohort study</i> —If applicable, explain how loss to follow-up was addressed <i>Case-control study</i> —If applicable, explain how matching of cases and controls was addressed <i>Cross-sectional study</i> —If applicable, describe analytical methods taking into account of sampling strategy (e) Describe any sensitivity analyses
Results		
Participants	13*	(a) Report numbers of individuals at each stage of study—for example, numbers potentially eligible, examined for eligibility, confirmed eligible, included in the study, completing follow-up, and analyzed (b) Give reasons for non-participation at each stage (c) Consider the use of a flow diagram
Descriptive data	14*	(a) Give characteristics of study participants (e.g., demographic, clinical, social) and information on exposures and potential confounders (b) Indicate the number of participants with missing data for each variable of interest (c) <i>Cohort study</i> —Summarize follow-up time (e.g., average and total amount)
Outcome data	15*	<i>Cohort study</i> —Report numbers of outcome events or summary measures over time <i>Case-control study</i> —Report numbers in each exposure category, or summary measures of exposure <i>Cross-sectional study</i> —Report numbers of outcome events or summary measures
Main results	16	(a) Give unadjusted estimates and, if applicable, confounder-adjusted estimates and their precision (e.g., 95% CI). Make clear which confounders were adjusted for and why they were included (b) Report category boundaries when continuous variables were categorized (c) If relevant, consider translating estimates of relative risk into absolute risk for a meaningful time period
Other analyses	17	Report other analyses done—for example, analyses of subgroups and interactions, and sensitivity analyses
Discussion		
Key results	18	Summarize key results with reference to study objectives
Limitations	19	Discuss the limitations of the study, taking into account sources of potential bias or imprecision. Discuss both direction and magnitude of any potential bias
Interpretation	20	Give a cautious overall interpretation of results considering objectives, limitations, multiplicity of analyses, results from similar studies, and other relevant evidence
Generalizability	21	Discuss the generalizability (external validity) of the study results
Other information		
Funding	22	Give the source of funding and the role of the funders for the present study and, if applicable, for the original study on which the present article is based

\*Give information separately for cases and controls in case-control studies and, if applicable, for exposed and unexposed groups in cohort and cross-sectional studies.

**Note:** An Explanation and Elaboration article discusses each checklist item and gives methodological background and published examples of transparent reporting. The STROBE checklist is best used in conjunction with this article (freely available on the Web sites of *PLoS Medicine* at <http://www.plosmedicine.org/>, *Annals of Internal Medicine* at <http://www.annals.org/>, and *Epidemiology* at <http://www.epidem.com/>). Information on the STROBE Initiative is available at [www.strobe-statement.org](http://www.strobe-statement.org).